

It should be mentioned that both stages of the last step, precipitation with acetone and recovery from a silica gel column, are not entirely satisfactory as a method of purification, since they are erratic and occasionally involve loss of toxic material. The silica gel column is, however, consistent and reproducible with respect to the known ninhydrin reactants.

Complete isolation and characterization of the toxic factor require operations on a scale larger than has been possible for us hitherto, but these are now in hand.

H. R. BENTLEY  
E. E. McDERMOTT  
J. PACE  
J. K. WHITEHEAD  
T. MORAN

Research Association of British Flour-Millers,  
Cereals Research Station,  
St. Albans.

<sup>1</sup> Mellanby, E., *Brit. Med. J.*, 288 (Aug. 23, 1947).

<sup>2</sup> Moran, T., *Lancet*, 289 (Aug. 23, 1947).

<sup>3</sup> Radomski, J. L., Woodward, G., and Lehman, A. J., *J. Nutrition*, 36, 15 (1948).

<sup>4</sup> Tiselius, A., Drake, B., and Hagdahl, L., *Experientia*, 3, 21 (1947).

<sup>5</sup> Albanese, A. A., *J. Biol. Chem.*, 134, 467 (1940).

<sup>6</sup> Partridge, S. M., *Chem. and Indust.*, 27 (1949).

### A Morphological Distinction between Neurones of the Male and Female, and the Behaviour of the Nucleolar Satellite during Accelerated Nucleoprotein Synthesis

GENETICISTS have long emphasized that 'maleness' and 'femaleness', so far as chromosome content is concerned, are projected from the fertilized ovum into the morphologically and functionally specialized somatic cells. It appears not to be generally known, however, that the sex of a somatic cell as highly differentiated as a neurone may be detected with no more elaborate equipment than a compound micro-

scope following staining of the tissue by the routine Nissl method.

The observations to be recorded here apply to the cat primarily, since the cat is used routinely in this laboratory for investigations in experimental neurocytology. The nuclei of nerve cells contain a prominent nucleolus which stains readily with such basic dyes as cresyl violet and thionin. The difference in nuclear structure between neurones of adult male and female cats rests on the degree of development of a second body, which is much smaller than the nucleolus. The latter body is more or less intimately associated with the nucleolus and, like the latter, stains well with basic dyes. It has been described by many authors under various names. The term 'nucleolar satellite' will be used in this report, in the hope that students of chromosome morphology will not object too strenuously to the use of the word 'satellite' in this connexion.

Typically, nerve cells of mature *female* cats contain a well-developed nucleolar satellite which is located, as a rule, immediately adjacent to the nucleolus (Fig. 1). A single satellite is usually present; but two may be encountered. The satellite, if more deeply stained than the nucleolus, may be seen in all nerve cells which are sufficiently large to have a prominent nucleolus. More often, the intensity of staining of the nucleolus and its satellite is similar. Under these conditions, the satellite is seen in approximately 30-40 per cent of cells, being invisible when eclipsed by the nucleolus.

As a rule, nerve cells of mature *male* cats (Fig. 2) contain a poorly developed nucleolar satellite, seen only infrequently. When visible, it is situated adjacent to the nucleolus and is near the limit of resolution with an oil-immersion objective.

In a small proportion of animals of both sexes, nucleolar satellites of intermediate size are present. These exceptional cases raise several interesting questions which are now under investigation.

The morphological distinction, therefore, between neurones of the mature male and female cat is so

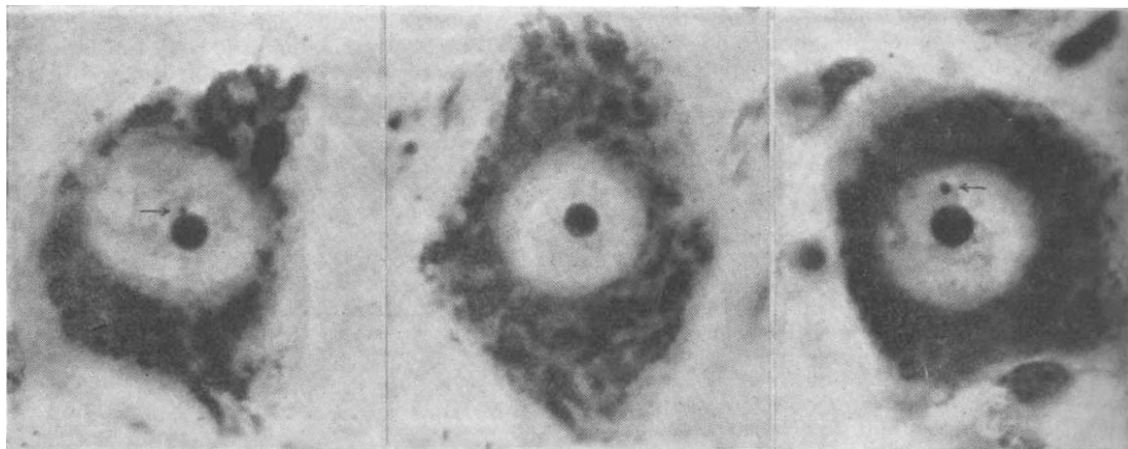


Fig. 1

Fig. 2

Fig. 3

Fig. 1. Normal motor neurone from the hypoglossal nucleus of a mature female cat showing the usual morphology of the nucleolar satellite (indicated by arrow) in the female. Cresyl violet stain,  $\times 1,400$

Fig. 2. Motor neurone from the hypoglossal nucleus of a mature male cat. The nucleolar satellite is absent, the typical condition in the mature male. Cresyl violet stain,  $\times 1,400$

Fig. 3. Motor neurone from the hypoglossal nucleus of a mature female cat 108 hours following electrical stimulation of the corresponding hypoglossal nerve for a period of 8 hours. Associated with intense synthesis of cytoplasmic ribose nucleoproteins, the nucleolar satellite (indicated by arrow) tends to move away from the nucleolus. Cresyl violet stain,  $\times 1,400$

clear that sections from the brain, spinal cord or sympathetic ganglia of animals of both sexes may be readily sorted into two groups without prior knowledge of the sex, with only an occasional section remaining in which the distinctive morphological feature is of an intermediate character.

That there should be a morphological difference in the inter-mitotic nucleus of mature, differentiated cells, according to their sex, is not surprising in view of what is known concerning the relation of the nucleolus to the chromosomes. The nucleolar chromosomes are frequently the sex chromosomes<sup>1</sup>. One may postulate that such is the case in the cat. The nucleolar satellite may be derived from the heterochromatin of the sex chromosomes. Further, the cells of the female cat, because of the duplicated X-chromosomes, may be endowed with a greater quantity of nucleolar associated heterochromatin than are the cells of the male cat. Caspersson and Schultz<sup>2</sup> noted a difference in the absorption curves obtained with ultra-violet light, indicating a difference in nucleoprotein content, in cells of male and female *Drosophila*. These comments suggest the importance of taking the sex into consideration in cytochemical studies of nucleoprotein metabolism.

A preliminary examination of sympathetic ganglia of human males and females indicates that a similar sex difference in nuclear morphology exists in the human. Whether or not such sex differences in nuclear structure will be found in a given species would probably be determined, in part, by the relationship of the nucleolus to the sex chromosomes and by the disparity in size and composition between the X- and Y-chromosomes. It is probable that somatic cells of various tissue, characterized by large nucleoli, will display similar distinctive nuclear differences according to the sex.

We wish to emphasize that these observations apply to mature animals. The influence of the age factor and other aspects of the nucleolar satellite under normal and experimental conditions will be published in later reports.

It is of interest to experimental neurocytologists that the position of the satellite relative to the nucleolus is a useful aid in assessing the physiological state of the cell. In a series of experiments, to be reported in detail elsewhere, depletion of the Nissl material of motor neurones was produced by prolonged electrical stimulation of the hypoglossal nerve. The nucleolus enlarges during the recovery phase, coincident with the re-appearance of abundant Nissl material in the cytoplasm. This observation is in agreement with the views of Caspersson and his co-workers, who regard the nucleolus and the nucleolar associated chromatin as instrumental in the synthesis of ribose nucleoprotein, an important component of the Nissl substance (see Hydén<sup>3</sup> for references). It is of particular interest in the present connexion that the satellite moves away from the nucleolus during the period of intense ribose nucleoprotein synthesis (Fig. 3). The satellite may, in these circumstances, lie in contact with the nuclear membrane. The movement of the nucleolar satellite may be passive, resulting from the outpouring of materials (nucleotides or nucleic acids?) from the region of the nucleolus. On the other hand, complex factors, such as forces of an electrical nature, may be at work. In any case, the position of the satellite is another item for observation, in addition to the appearance of the Nissl substance, in attempting to assess the physiological state of the neurone under experimental

conditions. This criterion may be applied to best advantage, of course, only to the cells of female cats. The nucleolar satellite is occasionally found free in the nucleoplasm in control cells. This is regarded as a further indication of the variation in the physiological state of members of a nerve-cell population under normal conditions.

It is hoped that this brief preliminary report may encourage closer attention to the nucleolar satellite in the abundant material available to laboratories of neuropathology in which the Nissl method is constantly in use as a routine staining technique. The possibility that fundamental alterations in the nucleolar associated chromatin may have an important bearing on malignancy gives added interest to these observations.

These observations were made in the course of experiments on the effect of activity on the neurone being done in this laboratory for the Institute of Aviation Medicine, Royal Canadian Air Force. The senior author wishes to thank various members of the staffs of the Department of Neuropathology, University of Toronto, and of the Montreal Neurological Institute, for very helpful discussions.

MURRAY L. BARR  
EWART G. BERTRAM

Department of Anatomy,  
University of Western Ontario,  
London, Canada.  
March 3.

<sup>1</sup> Gates, R. R., *Bot. Rev.*, **8**, 387 (1942).

<sup>2</sup> Caspersson, T., and Schultz, J., *Proc. U.S. Nat. Acad. Sci.*, **26**, 507 (1940).

<sup>3</sup> Hydén, H., *Symp. Soc. Exp. Biol.*, **1**, 152 (1947).

### Effect of a South African Native Diet upon Rats

YOUNG rats of the Wistar Institute strain aged five to six weeks and weighing 70–100 gm. were fed on the Gillman diet<sup>1</sup>. This consisted of liberal quantities of a thick mealie-meal porridge and fermented cow's milk. Animals were killed after they had been on this diet for four and a half and six months. All, except two in the latter group, showed an abnormal bromsulphalein retention in the serum; but the serum proteins, thymol turbidity, thymol flocculation and colloidal gold tests were within normal limits.

The following organs were examined histologically: liver, kidney, spleen, upper incisor teeth and periodontal tissues. The lower ends of the radii and ulnæ and the upper ends of the tibiæ were examined by the line test<sup>2</sup>. Microscopy of the livers revealed relatively little fatty change, but practically complete absence of glycogen in all except the two rats, which showed a normal bromsulphalein excretion. In these two rats the amount of glycogen present in the liver was normal. The kidneys and spleens of all animals showed no abnormal histological changes. Interesting pathological changes were, however, found in the incisor teeth and periodontal tissues, which are best described under three heads.

(1) The animals were suffering from a sub-acute vitamin A deficiency, which was not severe after four and a half months, but was much more marked after six months. This was seen in the teeth of the younger rats as a lack of regression of the odontoblasts, which